

# TOPICAL THERAPY FOR MACULAR HOLE

**Author**

Sai Meghana Paidi, B.S.

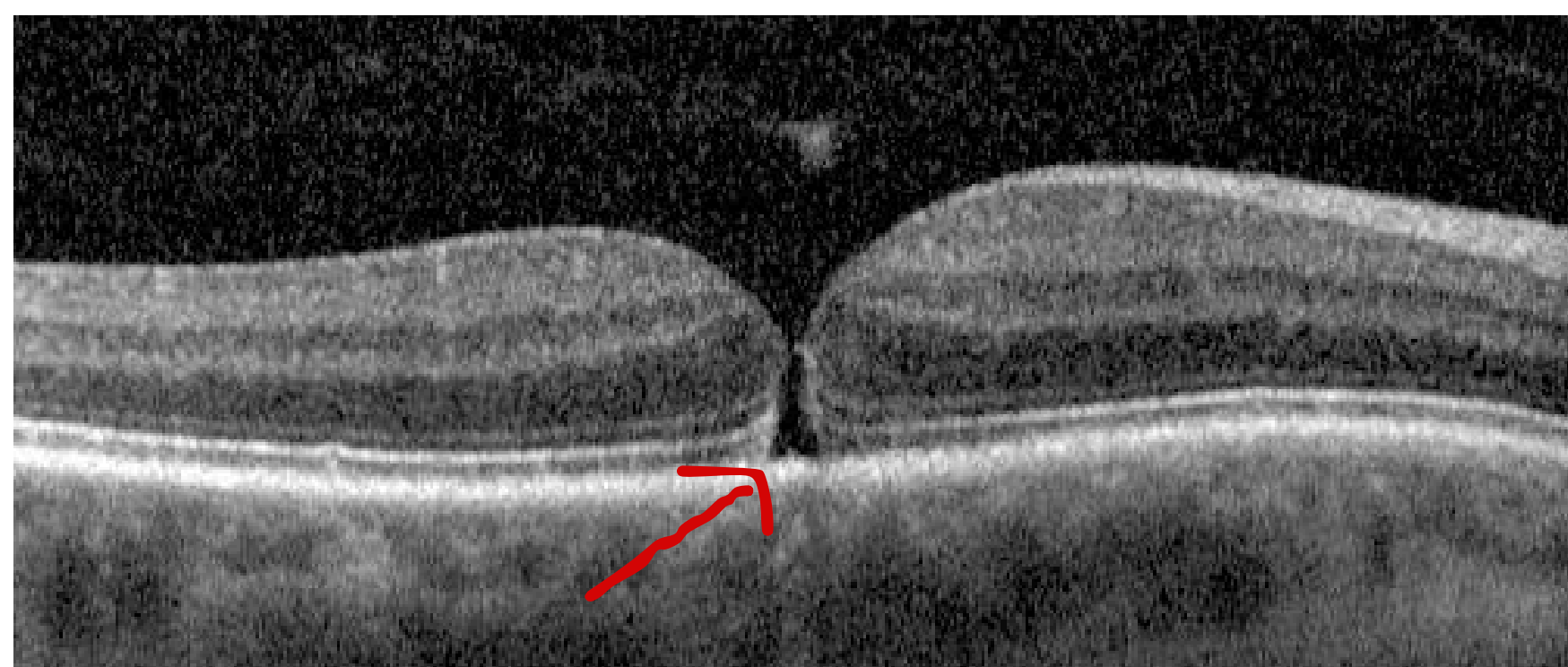

## History

A 58-year-old female patient was referred to our practice for evaluation of decreased vision in her right eye for one month. She works as a registered nurse and had no significant medical or ocular history.

## Examination

Visual acuity was 20/40 OD and 20/20 OS. Intraocular pressures were 17 mmHg OD and 15 mmHg OS. There was no RAPD. Examination of the posterior segment revealed a small full thickness macular hole (FTMH) in the right eye. These findings were confirmed by OCT imaging (Figure 1).



**Figure 1.** OCT of the right eye. The arrow indicates the small macular hole.

## Treatment

We discussed treatment options including vitrectomy surgery. However, due to the small size of the hole, we attempted topical therapy first. She was started on Ketorolac 0.5%, Prednisolone Acetate 1%, and Dorzolamide 2% all three times a day in the right eye. At the 6-week follow-up visit, the hole had improved (Figure 2, a) and at the 12-week follow-up, her vision improved to 20/25 OD and the hole closed (Figure 2, b).

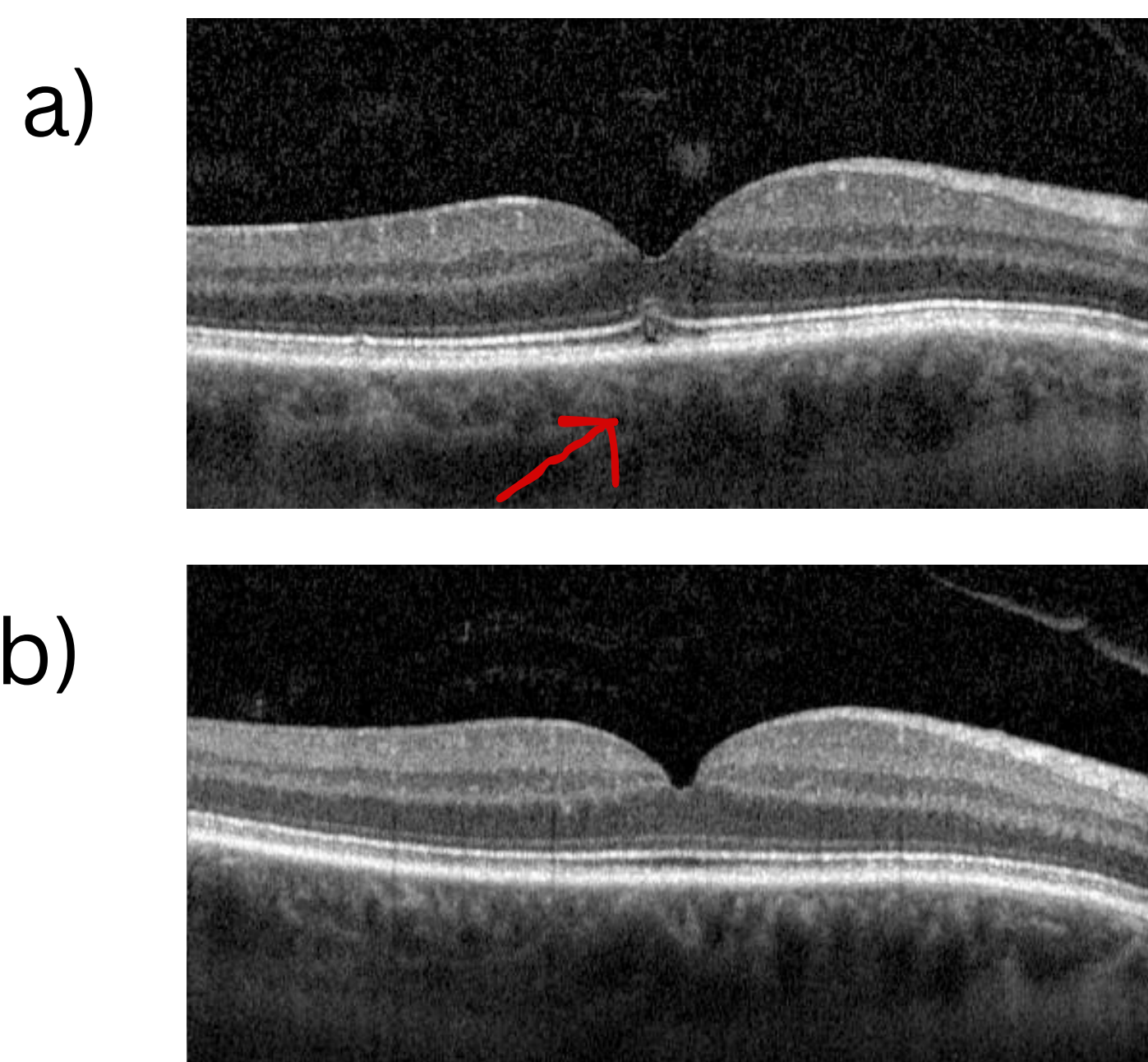
# TOPICAL THERAPY FOR MACULAR HOLE

**Author**

Sai Meghana Paidi, B.S.



FTMHs are caused by vitreoretinal traction of the posterior hyaloid on the fovea. Topical steroids, NSAIDs, and carbonic anhydrase inhibitors are thought to reduce inflammation and macular edema. Although long-term use of topical treatments needs to be studied, they can be used for small holes or potentially in patients when surgery may not be feasible.



**Figure 2.** OCT of the right eye at 6 weeks (a) and 12 weeks (b) after topical treatment was initiated.

## Locations

**Ann Arbor:** Reichert Health Building 5333 McAuley Dr, Suite 1018, Ypsilanti, MI 48197

**Dearborn:** 25230 Michigan Ave, Dearborn, MI 48124

**Novi:** 24520 Meadowbrook Rd, Suite 100, Novi, MI 48375

## Contact us

**Phone:** 313-441-2227

**FAX:** 313-441-2241



**Asheesh Tewari, MD**



**Michael Gemayel, MD**